



A video of this technique is available online

Open camera or QR reader and scan code to access this article and other resources online.

## Surgical Pearls for Safe and Precise Decision-Making during Modified Selective Neurectomy Surgery

AQ: au Berke Özücer, MD<sup>1-3,\*</sup> and Begüm Yılmaz, MD<sup>4</sup>

### Abstract

AQ: 1

In this short communication: (1) A TENS stimulator is a cost-effective solution for the predictable stimulation of mimicry and for precise decision-making. (2) Positioning a simple shatterproof mirror in front of an operated facial half enables the primary surgeon to simultaneously see and stimulate at the operative site and to scrutinize the mimicry for decision-making. (3) A misconception in the literature regarding colors used for tagging “branches for transection” and “branches for preservation” is clarified, and a third tag-color is suggested for times of ambiguity. (4) The principle of distal execution of the surgery and technical considerations are underlined for maximal transection and maximal preservation. The modified selective neurectomy surgery is the current golden standard of post facial paralysis synkinesis treatment, and developing a learning curve in this type of surgery is like walking a tightrope, where the surgeon must keep pushing the limits with precise decision-making and a small margin of error. It is important to be reminded that the first aim is *primum non nocere*, and the second aim is to improve the condition of patients as much as possible. The above-mentioned principles and solutions increase precision and safety, assisting surgeons to achieve better outcomes.

### Introduction

AQ: 2

The modified selective neurectomy (MSN) surgery technique was described by Azzizadeh et al. in 2019 for the treatment of smile dysfunctions due to post facial paralysis synkinesis (PFPS) (1). This case-series publication was followed by two other complementary publications that focused on the treatment of lower lip and brow deformities associated with non-flaccid facial palsy (2, 3). Only two other MSN case-series in the literature were published thereafter (4, 5).

F1

In this article, certain surgical tips and tricks that potentially increase precision and safe decision-making during MSN surgery are presented.

### Biphasic TENS Stimulator

In the discussion of their surgical technique, Azzizadeh et al. described that nerves were stimulated (0.5–2 mA) using a disposable Checkpoint Surgical nerve stimulator (1–3). A TENS device, which uses a biphasic waveform similar to Checkpoint to enable safe repeated stimulation without a diminished response, has also been routinely used (4).

It was used at preset P-15 module ([pulse width: 200 µs]). The frequency was 50 Hz, which is similar to the electronic specifications of the Checkpoint device) at 1 or 2 mA stimulation (TENStem Eco Basic 2, Schwa-Medico). The senior author (B.O.) of this article utilized this device safely in more than 70 selective neurectomy cases alone, in addition to innumerable parotidectomies

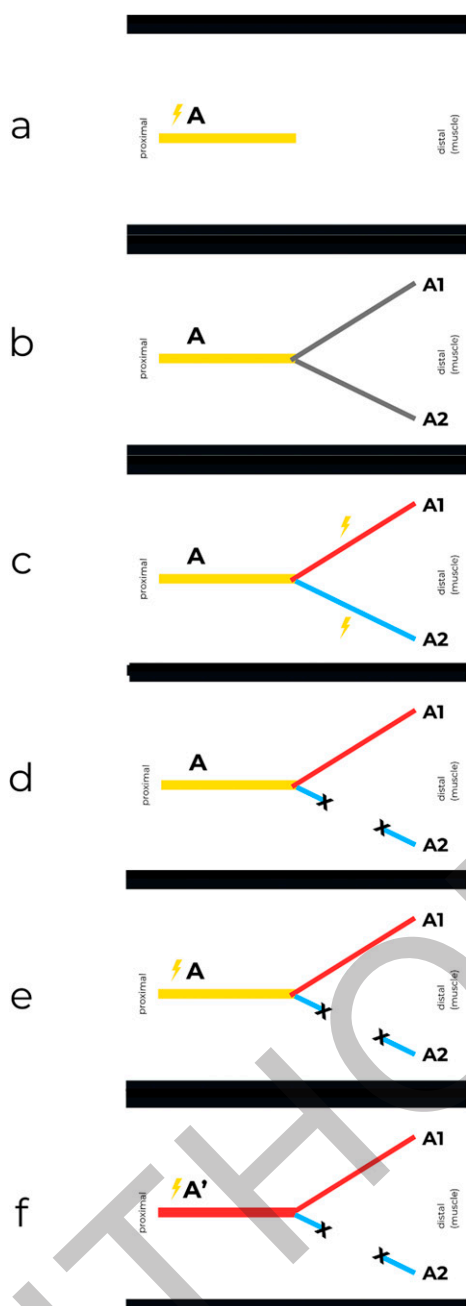
<sup>1</sup>Board Certified in Facial Plastic and Reconstructive Surgery EBCFPRS, IBCFPRS, Alexandria, Virginia, USA.

<sup>2</sup>Otolaryngology & Head and Neck Surgery Specialist, Doctor Be+ Private Clinic, Istanbul, Turkey.

<sup>3</sup>Department of Otorhinolaryngology and Head-Neck Surgery, Medical Faculty, Halic University, Istanbul, Turkey.

<sup>4</sup>Department of Otolaryngology Head and Neck Surgery, Kartal Dr. Lutfi Kırdar Training and Research Hospital, Istanbul, Turkey.

\*Address correspondence to: Berke Özücer, MD, Board Certified in Facial Plastic and Reconstructive Surgery EBCFPRS, IBCFPRS, Alexandria, Virginia, USA, Email: berkeozucer@gmail.com



**Fig. 1.** Demonstrative Case after Right Modified Selective Neurectomy. **(a)** Branch A is stimulated with a TENS stimulator and is tagged “yellow”. **(b)** Branch A is distally dissected: sub-branches A1 and A2 are found. **(c)** Sub-branches A1 and A2 are stimulated with a TENS stimulator. **(d)** Sub-branch A2 is tagged “blue” (transected). **(e)** Following sub-branch A2 transection, Branch A is restimulated. **(f)** Stimulation of Branch A now reveals good movement only and is tagged “red” and preserved.

AQ: 3

and deep plane facelift surgeries for nerve monitoring. Avoiding lidocaine and muscle relaxants during general anesthesia is adequate for predictable monitoring and consistent decision-making. The non-disposable nature of this device, wide availability, and lower cost make it an advantageous option, especially for surgeons in under-developed world countries.

### Shatterproof Mirror

Continuous critical decision-making, at every stage, is essential for satisfactory outcomes and to avoid complications in surgeries. This is even more so in MSN surgery. Innumerable stimulations and mimetic evaluations make it very cumbersome for simultaneous execution and decision-making. Getting verbal feedback from an assistant regarding mimicry creates dependency and can potentially decrease a surgeon’s overall control. A simple, commercially available, acrylic, non-glass shatterproof mirror (25 × 40 cm) will enable the surgeon to see the operative site and the face at the same time (Video). This significantly decreases the operative time and enables the surgeon to effortlessly stimulate and see the mimicry simultaneously, as many times as required.

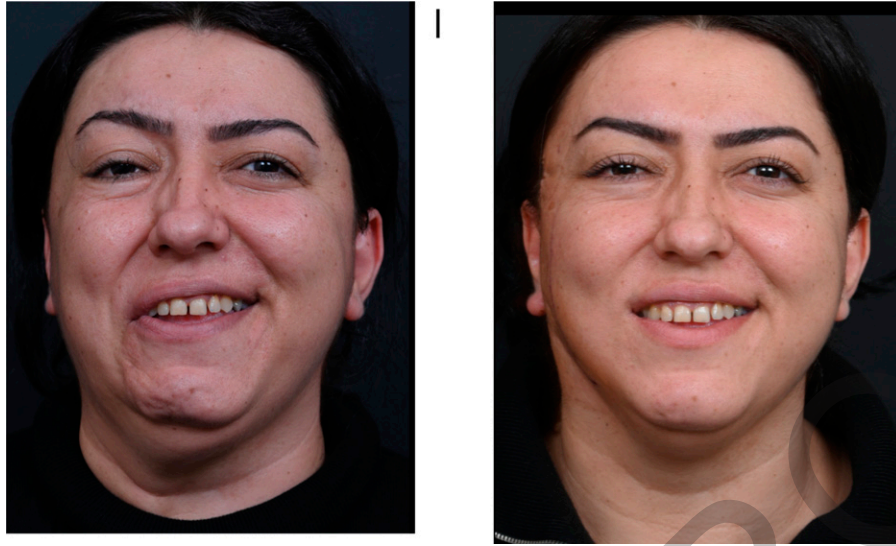### Nerve Tags and Third Color Tag for Ambiguity

The main principle in MSN surgery is transecting synkinetic branches maximally while preserving healthy branches maximally. Considering the associated weakness in PFPS, maximum preservation is of the utmost importance so as not to iatrogenically reduce the movement of the face even more. Azizzadeh et al. uses red vessel loops to mark facial nerve branches for preservation, whereas blue vessel loops mark branches for transection (1). Unfortunately, the opposite coloring has been suggested, thus the confusion (5, 6).

The initial coloring suggested by Azizzadeh et al. has been used by the senior author, as well as a third color (yellow) for branches in the grey-zone. This approach can be helpful, especially for novice surgeons, where the decision to transect or preserve is not so clear, or stimulating a nerve branch concludes with both a healthy and synkinetic movement. The vast diversity of facial nerve anatomy and interconnections between different sub-branches renders this type of surgery complex and, at times, fraught with ambiguity (7).

### Going as Distal as Necessary for Precise Decision-Making

The principle suggested is that, at all times of uncertainty, the branch should be tagged yellow and dissected distally to investigate less proximal sub-branches for a better understanding (Video). This will result in the sub-branching of a nerve fiber into “preservable” and “transectable” branches (Fig. 2). It is further suggested that the root branch (where initially tagged yellow) be re-stimulated, immediately following transection of a sub-branch (Fig. 2b). This principle requires



**Fig. 2.** Algorithm For Optimal Transection and Maximal Preservation. Demonstrative Case after Right Modified Selective Neurectomy Figure 2a (Left) Preoperative 2 b (Right) Postoperative Result \* (Postoperative Fig. Photographed at Postoperative first month and the result is surgery-only, No chemodenervation with botulinum toxin involved) Preoperative topdown complaints that were addressed (\*) (1) brow elevation and asymmetrical eye closure on paralytic side, limited teeth show and vertical discrepancy of mouth corner due to depressor anguli oris co-contraction, pinched upper and lower lip during smile, peau-de-orange around depressor anguli oris and mentalis, platysma co-contraction and overall feeling of tightness. (\*) Natural laugh induced by a joke.

that surgery be conducted as distally as the point where the nerves enter the muscles. Going distal is an important principle in preserving nerve fibers and transacting them optimally, whenever there is ambiguity (Video).

There are many interconnections between facial nerve branches (7), therefore following transection of a sub-branch requires the re-stimulation of other branches because mimicry can potentially change after transection (Example with referral to Fig. 2: Transection of A3 may lead to B branch becoming B' and resulting with changed mimicry)

### Conclusion

MSN surgery is already the golden standard of post facial paralysis synkinesis treatment. The learning curve in this type of surgery is akin to walking a tightrope, where the surgeon must keep pushing the limits with precise decision-making and a small margin of error. It is important to be reminded

that the first aim is *primum non nocere* and the second is to improve patients' conditions as much as possible. The above-mentioned principles and solutions have played a positive role in enhancing precision and safety in the authors' surgeries and hopefully will assist others to achieve better outcomes.

Caption: (Lightning symbolizes TENS stimulation) Algorithm.

AQ: 4

### Acknowledgments

The authors would like to express their gratitude and respect to all the giants upon whose shoulders they stand.

### Author Disclosure Statement

No competing financial interests exist.

### Funding Information

No funding was received for this article.

# AUTHOR QUERIES

## AUTHOR PLEASE ANSWER ALL QUERIES

**1**

AQau— Please confirm the given-names and surnames are identified properly by the colours.

■=Given-Name, ■= Surname The colours are for proofing purposes only. The colours will not appear online or in print.

AQ1—Please provide the spelled-out form of the following abbreviation, if necessary. Ignore if standard abbreviation: TENS

AQ2—Please confirm if the numbers provided as (1-7) in the text are reference citations, if yes, please provide reference list or delete the citations from the text.

AQ3—Figure 1 is not cited in text, please provide citation in text at an appropriate place.

AQ4—Please specify if “Caption” is the legend for Video, if not then provide legend for Video.